



Contents lists available at ScienceDirect

The Foot

journal homepage: www.elsevier.com/locate/foot



Case report

Reconstruction of bilateral spontaneous chronic idiopathic Achilles tendon rupture using LARS ligament: Case report[☆]

Mandeep S. Dhillon*, Devender Chauhan, Vishal Kumar, Uttam C. Saini

Dept of Orthopaedics, Post Graduate Institute of Medical Education & Research, Chandigarh, India

ARTICLE INFO

Article history:

Received 20 June 2010
Received in revised form
17 September 2010
Accepted 20 September 2010

Keywords:

Tendo-Achilles
Bilateral
Neglect
LARS ligament

ABSTRACT

Spontaneous bilateral idiopathic rupture of Achilles tendon is rare and usually results from sudden dorsiflexion of a plantar-flexed foot; the tendon is most often degenerated or diseased, and spontaneous bilateral rupture is not rare in patients suffering from chronic diseases. Management problems relate to reconstruction options and issues with early ambulation and weight bearing. We report a case of idiopathic bilateral Tendo-Achilles (TA) rupture with no obvious disease process, which was initially neglected, and subsequently reconstructed with LARS polyester ligament. The patient could be mobilized early despite bilateral involvement, but developed bilateral wound dehiscence which needed debridement and local flap coverage; aggressive rehabilitation finally leads to an excellent functional outcome. Despite the fact that artificial ligaments allow biointegration and can withstand stresses of early weight bearing, they often lead to wound related problems. Judicious use is advocated and good cases for their use maybe bilateral TA repair in neglected tears with gaps.

© 2010 Elsevier Ltd. All rights reserved.

1. Introduction

The Tendo-Achilles (TA) is the most frequently ruptured lower limb tendon and accounts for approximately 20% of all large tendon injuries [1]. Bilateral TA rupture is however not common; if it occurs, some predisposing issue like long term use of corticosteroid (as in SLE and RA), diabetes, xanthomatosis, chronic renal failure or use of fluroquinolones is usually found associated [2–4]. In the western population the reported incidence of TA rupture is around 0.02% in the general population; of these less than 1% are simultaneous bilateral ruptures [1].

Bilateral TA rupture is associated with significant morbidity because of rehabilitation problems after repair. Patients have difficulty with ambulation, as plaster immobilization of both ankles is needed to allow the injured tendon to heal. Management options become complex with both non-operative [5,6] and operative treatments [4,7–13] being described for this unusual injury. Reconstruction options become a problem when there is significant delay, and more so when the injury is bilateral. LARS (ligament augmentation & reconstruction system) is a range of synthetic ligament augmentation and reconstruction devices that have a variety of

applications as in ACL and PCL reconstruction and are used in ankle and shoulder repairs. Its use in bilateral neglected TA ruptures has not described in the literature.

A PubMed search done in June 2010 with keywords “Bilateral Tendo-Achilles rupture” gave 108 search results; but only 64 were relevant. Most of these highlighted etiological factors for bilateral Achilles rupture; while only few were focused on management options. The first case without any associated disease process was purportedly reported in 2009 [14]; but this was managed within 24 h. We report a case of idiopathic bilateral TA rupture seen with a significant period of neglect; since we opted for early ambulation in a bilateral scenario with significant gaps; the LARS ligament was used as an augmentation device in this unique situation.

2. Case report

A 45 years old male laborer had a low velocity road traffic accident while driving a bicycle. He developed immediate pain and swelling behind both ankles, and was unable to stand without support. A local practitioner diagnosed it as an ankle sprain, and partially immobilized the ankles, and the acute problem resolved within a few days of conservative treatment. The patient became partially ambulant, but presented to us 10 weeks after injury with difficulty in walking briskly and climbing stairs. On examination a bilateral gap of 5 cm was palpable 2 cm proximal to the calcaneal tuberosity. He had a positive Thomas calf squeeze test, Maltes test, and Copeland test, and was unable to stand without support or walk on tip-toes. A detailed medical history did not reveal any

[☆] This study was carried out at Post Graduate Institute of Medical Education & Research, Chandigarh, India.

* Corresponding author at: Dept of Orthopaedics, Post Graduate Institute of Medical Education & Research, House No. 92, Sector 24-A, Chandigarh 160023, India. Tel.: +91 9815951090.

E-mail address: drdhillon@gmail.com (M.S. Dhillon).

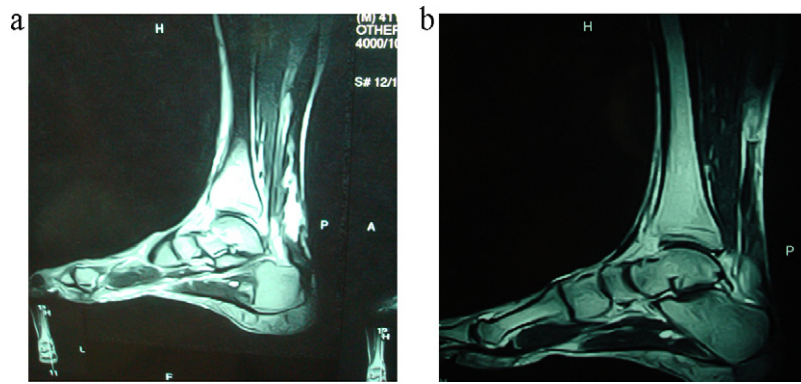


Fig. 1. Preop MRI – T1 and T2-weighted images showing large gap between tendon ends.

precipitating cause for this bilateral TA rupture and no abnormal blood investigations were noted.

MRI of both ankles showed significant gap in the ruptured TA ends; there was no evidence of any local pathology leading to this rupture (Fig. 1a and b).

Keeping in mind the delayed presentation and the significant gap between tendon ends, an artificial ligament augmentation using LARS ligament was planned (LARS – ligament augmentation & reconstruction system, 5 rue de la Fontaine, 21560 Arc sur Tille, France. Distributed by: Corin, The Corinium Centre, Cirencester, GL7 1YJ). LARS is composed of Industrial strength polyester fibers (Terephthalic Polyethylene). The surgery was done through a Lazy-S incision to expose the tendon and the frayed tendon ends were debrided; the gap could be reduced to 2 cm by pulling the ends and keeping the ankle in planter flexion, and so primary repair was not possible. We used LARS to bridge the gap, using the ligament threaded through a drill hole in the calcaneum, through the distal stump, and in a figure of ‘8’ manner through the proximal tendon end; the LARS ligament ends were sutured back on themselves with non-absorbable sutures, giving a stable construct.

Post operatively the ankles were immobilized in gravity equinus for 3 weeks; this was followed by an ankle neutral cast which was bivalved to start active ankle mobilization. Weight bearing was delayed as this was a bilateral case, and was initiated with Zimmer frame after 6 weeks. The patient developed bilateral wound dehiscence 3 weeks after surgery, for which he underwent initial wound debridement, which did not heal the problem. A local rotation flap was done bilaterally by a plastic surgeon 2 months after first surgery; this flap was only partially taken up on the right side, and some part of LARS became exposed. The patient continued to ambulate despite his wound related issue; he needed repeat surgical debridement for the exposed LARS in the right TA 9 months post surgery. It was noted that the wound dehiscence was at the site

where two ends of LARS were sutured with non absorbable sutures. Following excision of exposed tendon, the wound healed with secondary intention in three weeks duration (Fig. 2). The excised part of tendon had shown bio-integration on histological examination.

The patient subsequently developed a discharging sinus at 29 months post surgery posterior to the left ankle. Culture and sensitivity of discharge from sinus was sterile, and the sinus tract was excised with uneventful healing.

Repeat MRI done at 30 months follow-up showed good neo-tendon formation around the artificial graft and good bio-integration without allergic response in bony tunnels [in form of tunnel widening (Fig. 2a and b)]; no evidence of stretch lengthening of Tendo-Achilles was noted.

At last follow up of 37 months, range of movement in both ankle joints was 35° of planter-flexion (Fig. 3a) and 10° of dorsi-flexion (Fig. 3b). The patient was able to stand and walk on toes (Fig. 3c), which he was able to do since 3 months post surgery, despite local wound complications. At the end of 37 months the patient was independently mobile without pain, but with bilateral thickened Tendo-Achilles and adherent scar. Despite a relatively poor cosmetic outcome, the functional outcome was satisfactory in all respects, and the patient had gone back to his old job.

3. Discussion

Tendo-Achilles tears are problem scenarios at the best of times. Most often they occur through a degenerated tendon [15], or with some underlying cause that has weakened the tissue. Multiple solutions have been advocated for a primary reconstruction, with or without augmentation. The problem becomes compounded when the case is bilateral, as postoperative ambulation is often an issue. A period of neglect, as was seen in our case, further adds to the difficulty, as the retracted tendon ends cannot be brought together

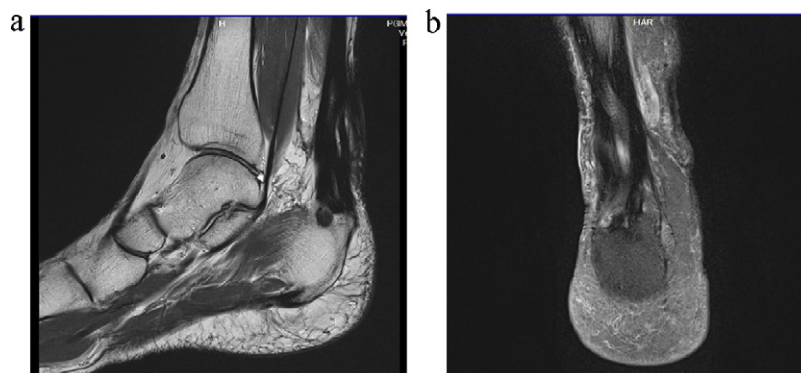

Fig. 2. Postop MRI – T1-weighted sagittal and coronal cuts showing good bio-integration of LARS ligament.

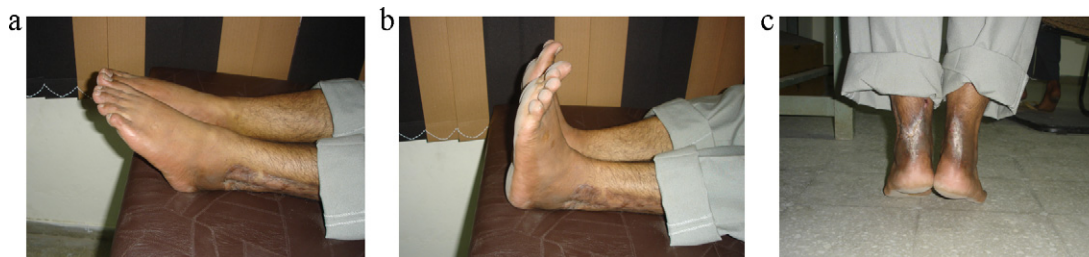

Fig. 3. Showing postop clinical outcome – plantar flexion (a), dorsiflexion (b) and standing on tiptoes (c). Note healed skin flaps.

without either proximal releases or autograft augmentation, and then rehabilitation has to be somewhat modified.

A PubMed search revealed sporadic case reports of bilateral Tendo-Achilles rupture but all except one [14] were associated with some illness, medication or degeneration; reported aetiological factors range from chronic renal disease, hypothyroidism, diabetes mellitus, SLE [16], to chronic steroid and fluoro-quinolones intake. Our case was unique because there was no underlying predisposing factor, and the delayed presentation had led to a 5 cm gap between tendon ends; we were also apprehensive that bilateral involvement would complicate the rehabilitation. We had planned augmentation of the repair of retracted tendon ends to minimize chances of failure [4,11], and planned to use a construct at the gap which would be biointegrated with time.

The available options in neglected TA rupture cases are lengthening of Gastro-soleus complex with V-Y plasty [1] or bridging the gap with autograft [8,12,13,17–19]. Problems associated with V-Y plasty are decrease in plantar flexion strength [7], and dissection and sliding of the flap probably render it devoid of a blood supply [10] even with careful dissection of the tissues. Tendinous autografts (e.g. flexor hallucis longus, flexor digitorum longus, peroneus brevis or fascia lata strips) are not strong enough to bear physiological load till 2–3 months and their use is always associated with subjective or objective graft related morbidity [4,17].

In the unique scenario of bilateral Tendo-Achilles rupture, where early ambulation is desirable, the option of artificial ligaments has also been explored by a few authors [2,10,18]. Polyester composed artificial ligament allows biointegration with crimp formation in a more natural way [9], which in the long term theoretically helps in preventing stretching and re-rupture of the repaired ligament. However, use of the artificial ligaments at this site of poor vascularity often comes with a price. The published literature, although scarce, has shown a significant rate of wound related problems with use of artificial ligaments for TA reconstruction, as was also the case in our patient. Jennings and Sefton [18] used polyester tape in 16 patients with chronic TA rupture and found excellent functional results after reconstruction despite 5.3% wound complication; one patient had persistent wound related problem that settled only after excision of tape. Akali and Niranjani [2] reported a case where Leed kieno ligament was used for repair of bilateral TA rupture and landed up with wound dehiscence on one side. Howard et al. [10] used carbon fiber for reconstruction and one patient in their study group developed non-healing wound for more than 10 months. The local area seems to be poorly susceptible to artificial implants, as even our patient developed bilateral wound problems and needed subsequent surgical interventions.

To the best of our knowledge, no consensus is available till date for management of bilateral, neglected TA rupture with significant gap. Our aim was to plan treatment in such a way that patient mobility would be hastened, with minimal immobilization related morbidity [3]. Reconstruction was also influenced by local tissue availability, especially in the bilateral setting. To achieve this goal we needed a material for surgical reconstruction of the

tendon, which had the ability to bridge the gap, and was strong enough to absorb pulls of the gastro-soleus complex without getting stretched; the property of bio-integration (essential to prevent fatigue failure), was an added bonus. LARS ligament was chosen for the reconstruction of this chronic rupture because it was expected to provide scaffolding for ingrowth of collagen tissue, which would induce biointegration and lead to ultimate incorporation in the tendon itself. The initial stability of the construct allowed us fairly early mobilization. However, our patient developed bilateral wound dehiscence which needed subsequent interventions; nevertheless, the reconstruction allowed aggressive rehabilitation, and the patient finally got an excellent functional outcome.

4. Conclusion

Bilateral Tendo-Achilles rupture without predisposing factors is unusual; in neglected cases the surgeon is often stumped for management options that could lead to early functional rehabilitation. Use of LARS ligament for reconstruction in this unique situation allows early and excellent functional recovery, but one has to be careful about wound healing issues in this zone of poor vascularity.

References

- [1] Habusta SF. Bilateral simultaneous rupture of the Achilles tendon. A rare traumatic injury. *Clin Orthop Relat Res* 1995;320(November):231–4.
- [2] Akali AU, Niranjani NS. Management of bilateral Achilles tendon rupture associated with ciprofloxacin: a review and case presentation. *J Plast Reconstr Aesthet Surg* 2008;61(7 (July)):830–4.
- [3] Gottschalk AW, Bachman JW. Death following bilateral complete Achilles tendon rupture in a patient on fluoroquinolone therapy: a case report. *J Med Case Rep* 2009;3:1.
- [4] Maffulli N. Rupture of the Achilles tendon. *J Bone Joint Surg Am* 1999;81(7 (July)):1019–36.
- [5] Lea RB, Smith L. Rupture of the achilles tendon. Nonsurgical treatment. *Clin Orthop Relat Res* 1968;60(September–October):115–8.
- [6] Lea RB, Smith L. Non-surgical treatment of tendo achillis rupture. *J Bone Joint Surg Am* 1972;54(7 (October)):1398–407.
- [7] Abraham E, Pankovich AM. Neglected rupture of the Achilles tendon. Treatment by V-Y tendinous flap. *J Bone Joint Surg Am* 1975;57(2 (March)):253–5.
- [8] Bosworth DM. Repair of defects in the tendo achillis. *J Bone Joint Surg Am* 1956;38-A(1 (January)):111–4.
- [9] Goodship AE, Wilcock SA, Shah JS. The development of tissue around various prosthetic implants used as replacements for ligaments and tendons. *Clin Orthop Relat Res* 1985;196(June):61–8.
- [10] Howard CB, Winston I, Bell W, Mackie I, Jenkins DH. Late repair of the calcaneal tendon with carbon fibre. *J Bone Joint Surg Br* 1984;66(2 (March)):206–8.
- [11] Mann RA, Holmes Jr GB, Seale KS, Collins DN. Chronic rupture of the Achilles tendon: a new technique of repair. *J Bone Joint Surg Am* 1991;73(2 (February)):214–9.
- [12] Turco VJ, Spinella AJ. Achilles tendon ruptures – peroneus brevis transfer. *Foot Ankle* 1987;7(4 (February)):253–9.
- [13] Wapner KL, Pavlock GS, Hecht PJ, Naselli F, Walther R. Repair of chronic Achilles tendon rupture with flexor hallucis longus tendon transfer. *Foot Ankle* 1993;14(8 (October)):443–9.
- [14] Garg S, Thilagarajah M. Bilateral rupture of achilles tendon (bilrat) without predisposing systemic disease or steroid use: a case report and review of the literature. *Internet J Orthop Surg* 2009;13(2) [a case report and review of the literature].
- [15] Lagergren C, Lindholm A. Vascular distribution in the Achilles tendon; an angiographic and microangiographic study. *Acta Chir Scand* 1959;116(5–6 (May)):491–5.

- [16] Murakoshi K, Momohara S, Ikari K, Iwamoto T, Kawamura K, Tomatsu T, et al. Neglected spontaneous rupture of the Achilles' tendon in patients with systemic lupus erythematosus. *Mod Rheumatol* 2006;16(5):324–6.
- [17] Hahn F, Maiwald C, Horstmann T, Vienne P. Changes in plantar pressure distribution after Achilles tendon augmentation with flexor hallucis longus transfer. *Clin Biomech (Bristol, Avon)* 2008;23(1 (January)):109–16.
- [18] Jennings AG, Sefton GK. Chronic rupture of tendo Achillis. Long-term results of operative management using polyester tape. *J Bone Joint Surg Br* 2002;84(3 (April)):361–3.
- [19] Suchak AA, Bostick GP, Beaupre LA, Durand DC, Jomha NM. The influence of early weight-bearing compared with non-weight-bearing after surgical repair of the Achilles tendon. *J Bone Joint Surg Am* 2008;90(9 (September)):1876–83.