

# Surgical Management of Traumatic Knee Dislocation

Samir Abdul Razik Ibrahim, F.R.C.S., M.D., Fawzy Hamido F. Ahmad, F.R.C.S., M.Ch.,  
Mahmoud Salah, M.D., Abdul Rahman Khalid Al Misfer, M.D.,  
Samy Abdul Ghaffer, M.Ch., and Shrief Khirat, M.D.

---

**Purpose:** The purpose of this study was to evaluate our method of surgical treatment of traumatic knee dislocation, by use of a standardized protocol, and to report our clinical results. **Methods:** Thirty-six consecutive patients presented with a grossly dislocated or reduced knee. Ten of these patients were not included in this series. Five had vascular or neurovascular injury. Three had open fracture dislocation, and two had associated severe injury. The remaining 26 patients were treated by primary arthroscopic reconstruction with autologous grafting of the anterior cruciate ligament, posterior cruciate ligament, and collateral ligaments. The anterior cruciate ligament and posterior cruciate ligament were reconstructed via the gracilis and semitendinosus tendons of the uninjured and injured limbs. The collateral ligaments were reconstructed via artificial ligaments (LARS Ligament; J. K. Orthomedic, Dollard-des-Ormeaux, Quebec, Canada). Of the 26 patients, 20 returned for subjective and objective evaluation at a minimum of 24 months after the operation. Early mobilization via a continuous passive motion machine and active exercise were started on the fourth day postoperatively. **Results:** At a mean follow-up of 43 months, the mean Lysholm score was 91 points, the mean score on the survey of daily activities was 90 points, and the sports activities score on the Knee Outcome Survey averaged 86 points. On the basis of the rating of Meyers et al., the results were excellent in 5 patients, good in 12, fair in 2, and poor in 1. The final International Knee Documentation Committee rating was not normal in any knee, nearly normal in 9, abnormal in 9, and severely abnormal in 2. The mean loss of extension was 0° to 2°, and the mean loss of flexion was 10° to 15°. **Conclusions:** By use of the described method of arthroscopic-assisted reconstruction of the cruciate ligaments and repair or reconstruction of the collateral ligament and other injured structures, 45% of the patients had good subjective results and functional stability and 45% had satisfactory subjective and functional stability within 2 to 3 weeks after surgery. According to the International Knee Documentation Committee scale, 45% of knees were nearly normal, 45% were abnormal, and 10% were severely abnormal. No patient's rating returned to normal. **Level of Evidence:** Level IV, therapeutic case series. **Key Words:** Knee dislocation—Cruciate ligaments—Collateral ligaments—Autologous graft.

---

**T**raumatic knee dislocation is an uncommon injury. The incidence may be higher than recorded because of spontaneous reduction or because the reduc-

tion was performed at the site of the accident and not recorded.<sup>1</sup> Most of the dislocations occur as a result of high-velocity injuries, mainly road traffic accidents, yet dislocation can also occur from low-velocity injury, as in sports. The associated morbidity is significant because of vascular and neurologic damage.<sup>2</sup>

Urgent operative treatment is indicated in patients with an irreducible dislocation, in patients with open dislocation, and in cases in which there is vascular injury.<sup>2-5</sup> Complete dislocation of the knee is possible without disruption of the posterior cruciate ligament (PCL).<sup>6,7</sup> The management of ligamentous injuries of the dislocated knee is variable, with one option being

---

*From the Department of Orthopaedics, Ministry of Health, Al-Razi Hospital, Safat, Kuwait.*

*The author reports no conflict of interest.*

*Address correspondence and reprints requests to Samir Abdul Razik Ibrahim, F.R.C.S., M.D., Department of Orthopaedics, Ministry of Health, Al-Razi Hospital, PO Box 4235 Safat, 13043 Kuwait. E-mail: samirabdulrazik@yahoo.com*

*© 2008 by the Arthroscopy Association of North America*

*0749-8063/08/2402-6555\$34.00/0*

*doi:10.1016/j.arthro.2007.08.007*

initial immobilization followed by active rehabilitation.<sup>8,9</sup> Advocates of this option claim that it results in a pain-free, stable knee with a mean of at least 90° of flexion.

Another option is early ligament repair, and its proponents have reported good results.<sup>10-16</sup> Recently, it has been reported that early ligamentous reconstruction using allografts has also yielded good results.<sup>17-19</sup> Autologous grafts have also been used for anterior cruciate ligament (ACL) and PCL reconstruction and repair of the collateral ligaments.<sup>20,21</sup>

There are currently no reports in the orthopaedic literature describing a consistent surgical arthroscopic approach for the management of these patients with autologous grafts of the gracilis and semitendinosus tendons of the uninjured and injured limbs for reconstruction of the ACL and PCL or reconstruction of the collateral ligaments using artificial graft (LARS Ligament, made of terephthalic polyethylene polyester fibers; J. K. Orthomedic, Dollard-des-Ormeaux, Quebec, Canada).<sup>22-24</sup> This study presents the results of arthroscopic reconstruction of the ACL and PCL and collateral ligaments by use of these grafts and implementation of a standardized program of rehabilitation in all cases. The purpose of this study was to evaluate the clinical results of surgical treatment of knee dislocation by use of a standard treatment protocol including continuous passive motion (CPM) at 4 to 5 days and complete reconstruction within weeks.

## METHODS

Thirty-six patients with either obvious or reduced traumatic knee dislocation were evaluated between 1995 and 2002. We retrospectively reviewed the records of all traumatic knee dislocations that had been treated by our standard protocol. Of the 36 patients, 10 were excluded because 5 had vascular or neurovascular injuries and needed urgent vascular surgery and 3 had open fracture dislocation; these were treated by external fixation. In addition, 2 had multiple severe injuries. The remaining 26 patients underwent standard preoperative evaluation, surgical management, and postoperative rehabilitation.

### Preoperative Assessment

After a detailed history was obtained and clinical examination and careful assessment of neurovascular status were performed, standard radiographs were obtained. CPM was used 4 or 5 days after the injury to achieve good range of movement before surgery or to

keep the knee statically flexed to 90° to 100° during surgery to reduce swelling and hematoma and to maintain joint movement after surgery. Surgery was performed 2 to 3 weeks after the injury, at which time patients had achieved nearly full range of motion, and time was allowed for healing of the soft tissues. Addressing all injured ligaments, an early rehabilitation program was started on the fourth postoperative day, by use of the CPM machine.

### Surgical Treatment

Examination with the patient under anesthesia was performed with the use of the contralateral knee as control. A tourniquet on the proximal part of the thigh was used in all patients. Our protocol is to perform reconstruction of the ACL and PCL with autologous graft (semitendinosus and gracilis tendon) of the injured knee and of the contralateral knee. Reconstruction of the medial and lateral ligaments was performed using artificial grafts. Any remaining injuries to the posterolateral corner were treated by direct repair, with peripheral meniscus tears being directly repaired in addition to capsular avulsion, whereas any central meniscus tear was excised to a stable rim.

**Skin Incision:** A marker was used to indicate the patella, the tibial tubercle, the fibular head, and the surface anatomy of the common peroneal nerve in a posterolateral dislocation. Anterolateral, anteromedial, and posteromedial portals were made under direct visualization with the use of the inside-out technique, if there was not marking on the skin. A 4-cm incision medial to the tibial tubercle on the proximal part of the tibia was made for the tibial tunnels of the ACL and PCL. A 2-cm incision was applied medially to the medial trochlear articular surface for the PCL femoral tunnel.

If there was a medial ligament injury, a 2-cm incision was made over the medial epicondyle and the graft was routed underneath the soft tissue from one incision to the other incision on the tibia. For the posterolateral corner, we used an incision extending between Gerdy's tubercle and the fibular head to the lateral epicondyle; this incision can be extended to explore the common peroneal nerve. An arthroscope was used, and diagnostic arthroscopy was performed to assess the cruciate ligaments, menisci, and articular cartilage. A 70° arthroscope could be placed through the anterolateral portal to visualize the tibial insertion of the PCL and the posteromedial portals that were to be used.

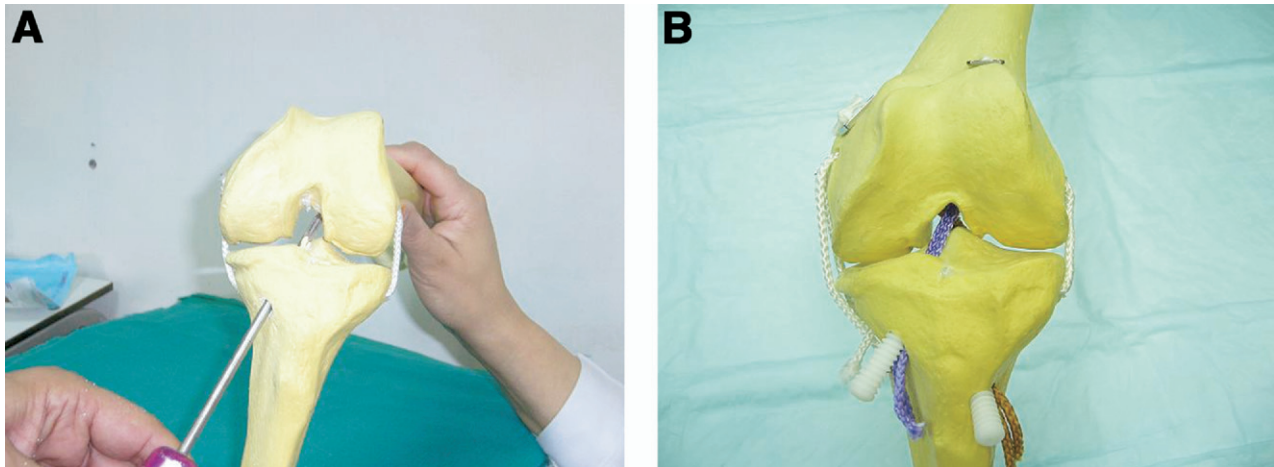


FIGURE 1. (A) ACL tunnels. (B) Fixation of ACL at 30°.

**Meniscus Injury:** We usually tried to preserve most of the tibial footprint of the ACL and to debride the knee joint. Notchplasty was performed in some cases to improve visualization and to prevent ACL impingement, and peripheral meniscal tears were repaired whereas central tears were debrided to a stable rim.

**Preparation of ACL Tunnels:** For the tibial tunnel, the tibial guide was placed through the anteromedial portal and the guide pin was positioned pointing at the native ACL tibial insertion (Fig 1). The tibial tunnel was formed by use of a series of cannulated drills, and the diameter of the drilled channel was calculated to correspond to the diameter of the transplant.

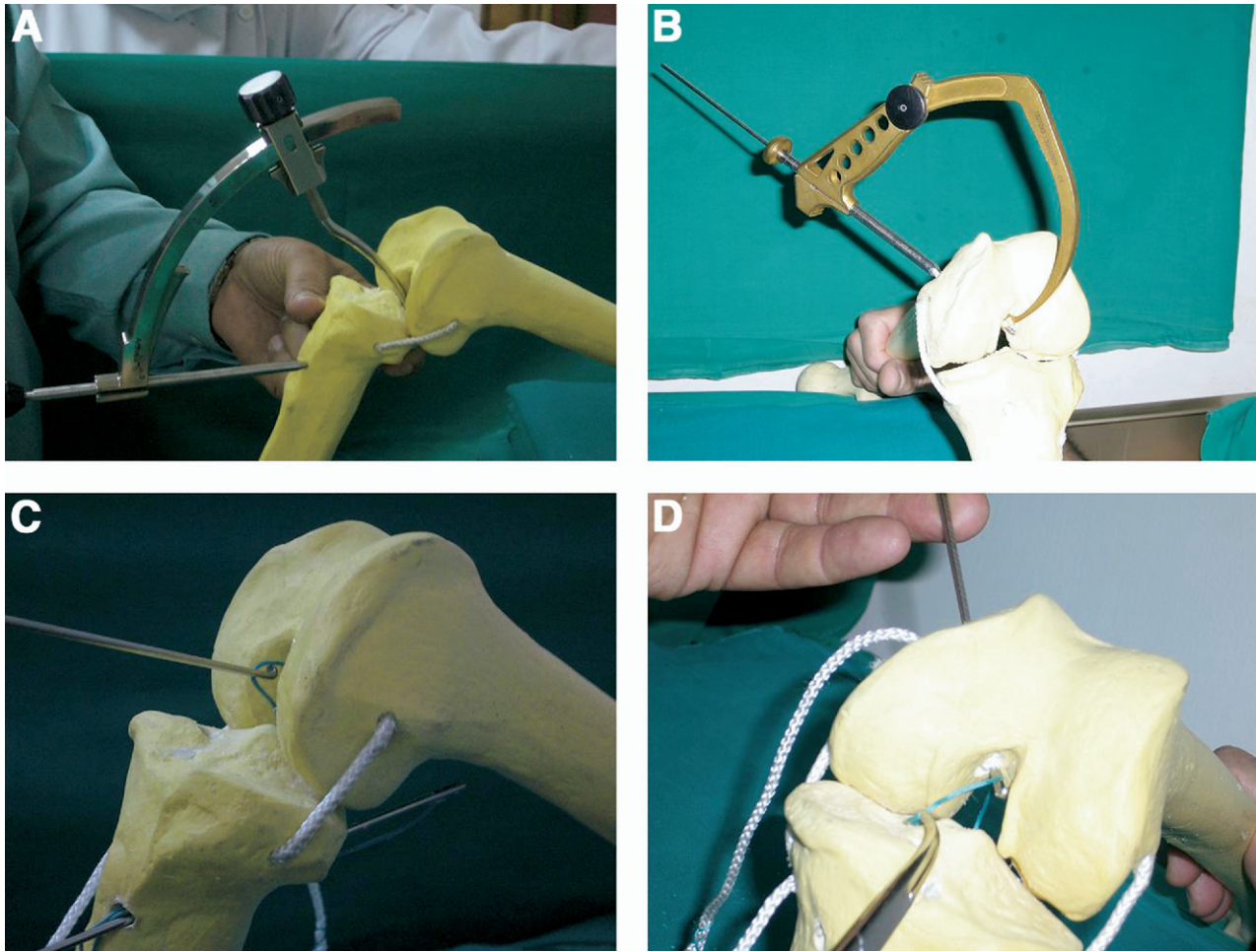
The femoral tunnel was formed by use of the femoral drill guide with a 5-mm offset hook (Smith & Nephew Endoscopy, Andover, MA), with the knee flexed to 90°. Of note, there must be at least 19 mm of tendon in each tunnel and the depth of the tunnel in the femur should be at least 7 mm longer than the length of the tendons that are to lie in the tunnel; this is to allow for turning of the EndoButton (Smith & Nephew Endoscopy). The femur was drilled arthroscopically with reamers. Of note, the diameter of the drill channel should correspond to the diameter of the transplant. A further hole was drilled from the tip of the femoral tunnel to the lateral cortex of the femur over the pullout pin with a cannulated 4.5-mm drill.

**Preparation of PCL Tunnels:** For the tibial tunnel, a curved rasp was inserted first to remove the PCL remnant from the posterior slope of the tibial spine (Fig 2A). The Arthrex PCL tibial marking hook (Ar-

threx, Naples, FL) with the attached adapter drill guide was inserted through the anteromedial portal, 10 mm distal to the posterior tibial cartilage. Of note, the tibial tunnel entry should be approximately 5 cm distal to the joint line and on the lateral side of the tibia. A guide pin was inserted until it reached the marking hook and could be seen and felt (with the position of the pin being confirmed radiographically), penetrating the posterior aspect of the tibia. A popliteal protractor cap was inserted through the anteromedial portal over the end of the guide pin; an appropriately sized full-thickness cannulated drill was selected; and the tibial tunnel was drilled.

For the femoral tunnel, we used an Arthrex PCL femoral marking hook attached to the adaptive guide and inserted it through the anteromedial portal (Fig 2B). The femoral tunnel was drilled over the drill guide pin through an incision over the medial femoral condyle. In most of our cases, either the menisiofemoral ligament or the posteromedial bundle (or both) was found intact and we preserved this intact part.

**Medial Ligament:** An incision was made over the medial epicondyle at its native attachment, a drill hole corresponding to the size of the artificial ligament was made, and another drill hole of the same size was made at the attachment of the medial ligament at its tibial attachment (Fig 3). The ligament was passed through the femoral tunnel and through the tibial tunnel. The ligament was sutured to its native ligament, if possible, and fixed with a staple over the tibial attachment. The knee at this stage was flexed to 90°.



**FIGURE 2.** (A) PCL tibial tunnel. (B) PCL femoral tunnel. (C) Pulling out pin with thread. (D) Passage of thread through femoral tunnel. Figure continued on next page.

**Lateral Ligament and Posterolateral Corner:** A lateral incision was made, extending between Gerdy's tubercle and the fibular head to the lateral epicondyle of the femur. The nerve around the fibular head was identified; repair and reconstruction were then performed with the knee flexed to 30°. Peripheral tearing of the lateral meniscus was repaired with the use of nonabsorbable sutures. Repair of the lateral structures was then performed, with sutures first being inserted through the peripheral capsule and then passed through a drill hole in the tibia. The arcuate complex was identified and tagged by several sutures, which were later drawn to its origin on the tibia. The popliteus tendon was retrieved and passed through a bone tunnel. None of the sutures was tied at this stage. A bone tunnel was created at the head of the fibula, and a similar tunnel was created at the lateral epicondyle,

at the attachment of the lateral ligament. The sutures of the posterolateral corner were tied. The artificial graft was passed through the tunnels and sutured on itself and was then fixed to the lateral epicondyle with anchors and sutures to the native lateral ligament, which had usually ruptured at the midsubstance. After repair of the collateral ligaments was completed, the knee was flexed to 90°.

**PCL Graft:** An Ethibond loop (Ethicon, Somerville, NJ) connected to the eye of the pullout pin was passed in a retrograde manner through the tibial tunnel of the PCL and then passed through the femoral tunnel to come out at its proximal end. The PCL graft was looped with the Ethibond, and the pullout pin was pulled down until the graft came out through the distal end of the tibial tunnel and the EndoButton lay on the cortex of the femur (Fig 2C-F).

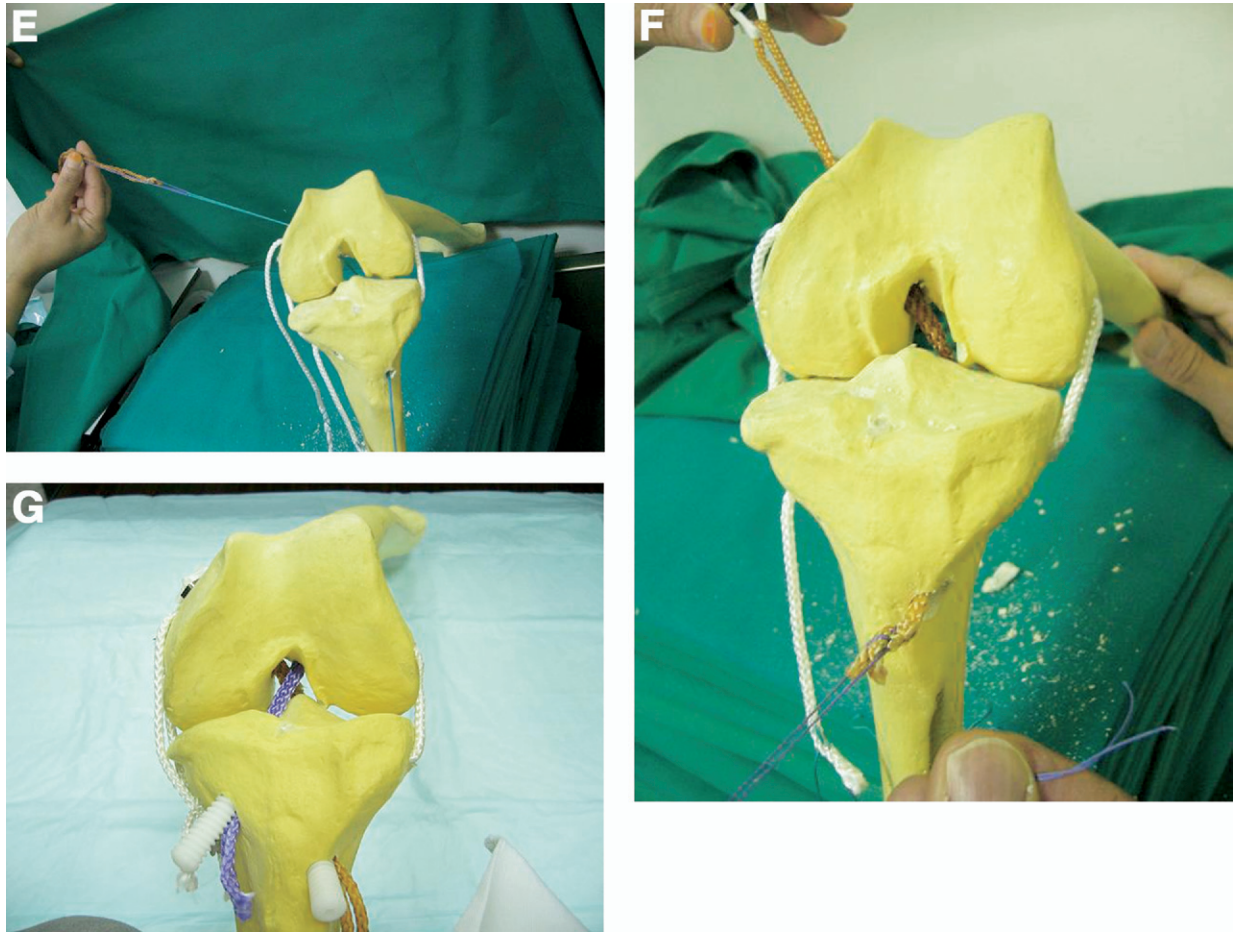


FIGURE 2. Continued (E) Retrograde passage of graft. (F) PCL graft through both tunnels. (G) Fixation PCL at 90°.

**ACL Graft:** The graft was marked with a surgical pen and was then passed through the tibial and femoral tunnels via pull-and-flip sutures and pulled through the eye of the pullout pin (Fig 1B). The pullout pin was inserted through the drill channel and out through the skin of the thigh. The pull suture must be the first to enter the femoral channel. When the graft had been pulled through the knee to the mark on the tendon, the leading and trailing sutures were then pulled, and this turned the suture EndoButton parallel to the femur, pulling back the graft so that the EndoButton lay on the lateral cortex of the femur.

Once the grafts of the ACL and PCL were secured on the femoral side, the knee was flexed to 90° and the PCL graft was tensioned and fixed at 90°; the knee was then placed in 20° of flexion, and the ACL graft was tensioned and secured. Both grafts were fixed with tibial interference screws (Johnson & Johnson Gateway, Piscataway, NJ) (Figs 4-6).

### Rehabilitation

The limb was placed in an above-knee back slab in full extension for the first 4 days postoperatively. Exercise immediately after surgery included passive knee extension and isometric quadriceps exercise with the knee in full extension. On the fifth day, the wound was inspected, and the patient's limb was attached to a CPM machine ranging from 0° to 30°; this was gradually increased from 60° to 90° according to the patient's tolerance. Active and passive exercise started in the third week. Patients were allowed to use crutches once they were able to do straight leg-raising. Weight-bearing was progressed from partial weight-bearing at 2 to 3 weeks to full weight-bearing as tolerated. Balance and proprioception exercises were started as soon as the patients were able to walk with full weight-bearing (at 4 to 6 weeks). Sedentary workers were able to return to work within 8 to 10 weeks,

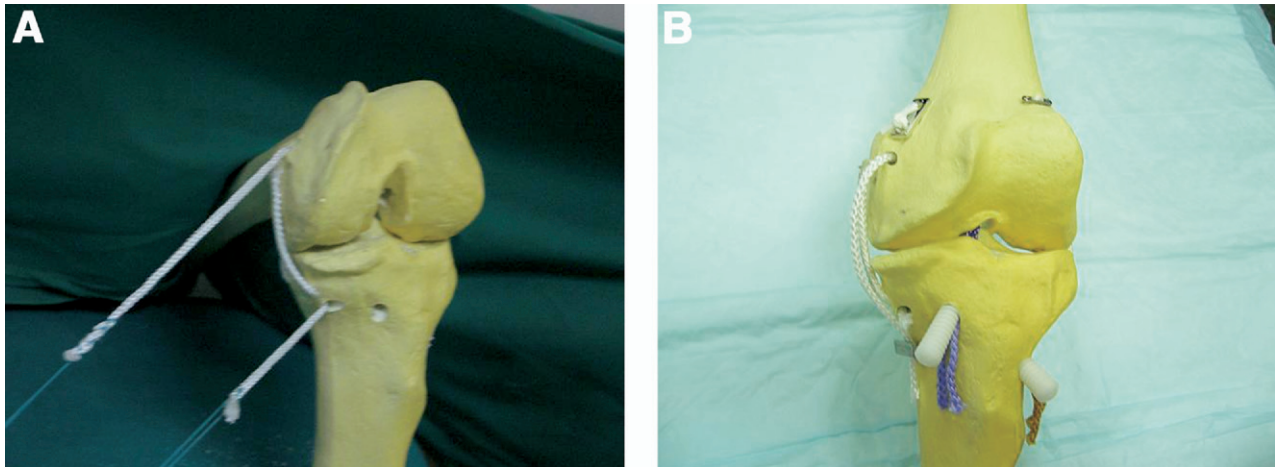


FIGURE 3. (A) Medial collateral ligament tunnels with graft. (B) Fixation of medial collateral ligament with staple.

whereas those with strenuous jobs did not return to work until 7 to 10 months postoperatively. Return to sports activities was not permitted before 12 months. The mean hospital stay after surgery was 10 to 14 days (because of the use of CPM machine, which could not be taken home and was an inpatient-only program at the time of the study).

**Follow-up and Assessment**

Clinical assessment included completion of a series of self-administered questionnaires (Knee Outcome Survey),<sup>25</sup> which assess a variety of knee disorders. The survey consists of 2 scales: activities of daily living and sports activity. The first scale ranges from

0 to 100 points, indicating an absence of symptoms and functional limitation during activities of daily living. The second scale measures symptoms and functional limitation felt during sports activities.<sup>26</sup> All patients underwent physical examination (by one of the authors) that included evaluation of range of motion and stability. Stability was assessed manually and with a KT-1000 arthrometer (MEDmetric, San Diego, CA). Examination with the arthrometer was performed with the knee at the quadriceps-neutral angle to determine the corrected anterior and posterior translation.

Functional assessment was graded as excellent, good, fair, or poor as proposed by Meyers et al.<sup>12,27</sup>

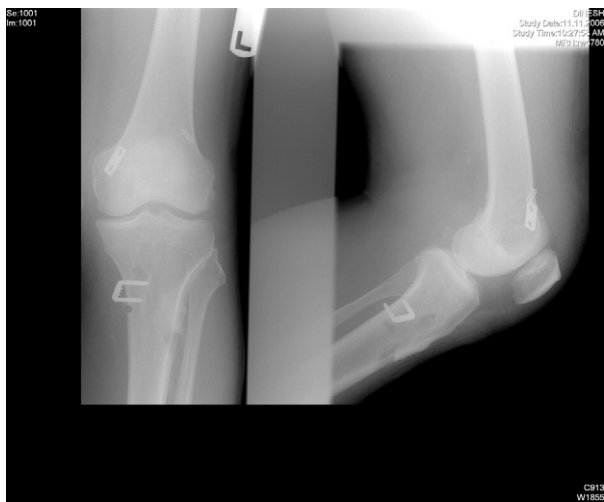

FIGURE 4. Proximal graft fixation of the ACL with an Endo Button and of the PCL with a miniplate.

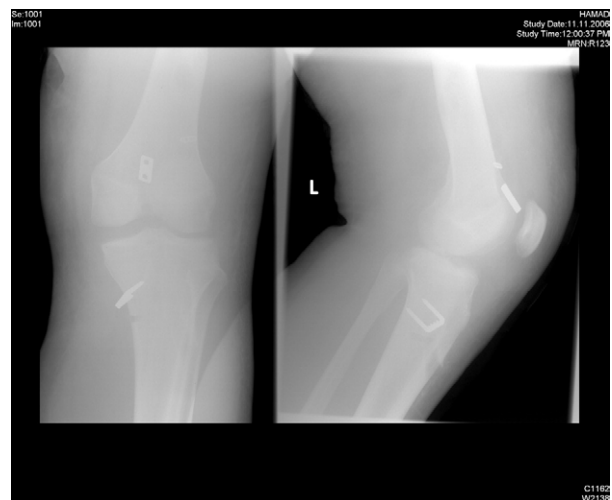


FIGURE 5. Distal graft fixation with intrafix and staple.

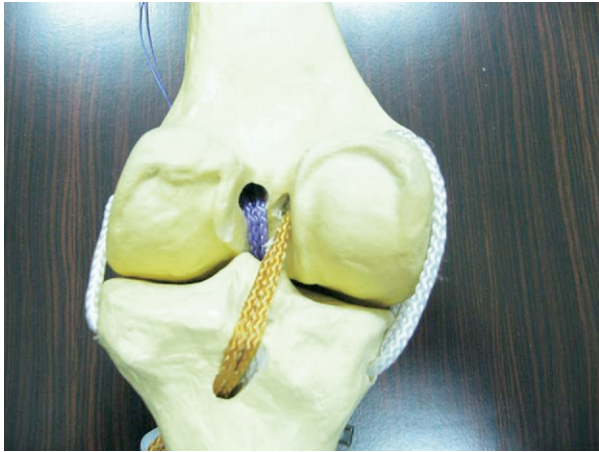

FIGURE 6. Postoperative view of knee.

Patients who were able to return to work and had no symptoms or instability were graded as excellent. Those with mild pain and instability that did not preclude a return to work were graded as good, those with considerable instability were graded as fair, and those who were disabled and unable to return to work because of pain or instability were graded as poor. The Lysholm knee score was used to assess the functional results.<sup>28</sup> The Lachman test and the anterior drawer test were performed. Care was taken to ensure a normal tibiofemoral step-off before application of stress to the tibia. Assessment of varus and valgus stability was determined at 30° of flexion. The final overall International Knee Documentation Committee (IKDC) rating was determined as recommended by Hefti et al.<sup>29</sup>

## RESULTS

Twenty patients were available for evaluation at a mean of 53 months (range, 36 to 96 months). The mean age of these patients at the time of surgery was 27.3 years (range, 17 to 45 years). Ten patients had been injured in an automobile accident, 6 in a work accident, 2 in a motorcycle accident, and 2 during sports activity. All patients underwent surgery after 2

TABLE 1. Clinical Results After Surgery in 20 Patients

Grade	Valgus Instability	Varus Instability	Anterior Drawer	Lachman Test	Posterior Drawer
Negative	14	1	13	15	10
1+	1	2	5	4	6
2+	—	2	2	1	4

TABLE 2. Lysholm Knee Score

Lysholm Knee Score	No. of Patients
88-97	6
80-87	13
78-79	1

weeks (range, 15 to 21 days). Examination under anesthesia and arthroscopy showed that 15 patients had a torn ACL, PCL, and medial, ligament, whereas 5 had a torn ACL and PCL and injury to the posterolateral corner. Of these 5 patients, 3 underwent reconstruction of the lateral ligament and repair of the posterolateral structures. Two patients had repair of an avulsion of the collateral and biceps femoris onto the fibular head.

## Clinical Results

Clinical results were evaluated by subjective patient assessment by use of a questionnaire and physical examination. The mean activities of daily living score on the Knee Outcome Survey was  $90 \pm 5.4$  points (range, 72 to 98 points), and the mean score on the sports activities scale was  $86 \pm 8.5$  points (range, 60 to 95 points). Of the 20 patients, 13 rated their outcome as excellent or good, 6 as fair, and 1 as poor. Physical examination showed that the mean loss of extension was 1° or 2° (range, 0° to 2°). Only 3 patients had slight flexion contracture. Four patients lost between 5° and 15° of flexion (with two having lost between 5° and 10° of flexion and two having lost between 10° and 15°).

On examination of the injured knee compared with the uninjured knee, the Lachman test was negative in 15 patients, grade 1 in 4 patients, and grade 2 in 1 patient. The posterior drawer test was negative in 10 patients, grade 1 in 6 patients, and grade 2 in 4 patients. Varus stress testing at 30° revealed that 2 patients had 1+ laxity, 2 patients had 2+ laxity, and 1 patient had no varus laxity (only 5 patients had preoperative laxity). Valgus stress testing at 30° showed that 10 patients had less than 3 mm of increased laxity and 5 had 1+ laxity (Table 1). The mean Lysholm knee score was  $91 \pm 4$  points (range, 78 to 100 points) (Table 2). Whereas the Tegner activity score decreased in all patients (Table 3), the Meyers functional rating showed that the result was excellent in 5 patients, good in 12, fair in 2, and poor in 1.

The KT-1000 arthrometer showed a mean corrected side-to-side difference of 0.1 mm (range, -3 to 2.5

**TABLE 3.** *Tegner Activity Score*

Tegner Activity Score		
Preoperatively	Postoperatively	No. of Patients
8-9	4-7	5
6-7	5-7	10
5-6	4-5	5

mm) in anterior translation and 2.6 mm (range, -1 to 8 mm) in posterior translation. The mean corrected side-to-side difference in anterior tibial translation was less than 3 mm in 15 patients, 3 to 5 mm in 4 patients, and more than 5 mm in 1 patient. The difference in posterior translation was less than 3 mm in 12 of 20 patients and between 3 and 5 mm in 6 patients; the remaining 2 patients had more than 5 mm of increased corrected posterior translation. The final IKDC rating was not normal in any patient, nearly normal in 9, abnormal in 9, and severely abnormal in 2 (as a result of a loss of flexion and consequent symptoms) (Table 4).

**Complications**

There was postoperative stiffness in 3 patients, all of whom were treated with manipulation under anesthesia (correcting loss of flexion) and arthroscopic release of adhesions. One patient had fracture of the tibia during fixation of the graft with screws and staples; he was treated with a below-knee cast for 6 weeks, and his fracture healed well. One patient sustained a hematoma in the uninjured limb, needing incision and drainage. Another complained of hypoesthesia along the medial aspect of the leg. The symptoms resolved in both patients.

**DISCUSSION**

Traumatic knee dislocation is a serious injury. The dislocation may be associated with vascular or neural injury (or both). The incidence of vascular injury has been reported as 30% to 50%.<sup>7,30</sup> Some authors advise arteriography in all cases of dislocation of the knee.<sup>31-33</sup> Associated nerve injury often involves the common peroneal nerve and has been reported in 25% to 40% of cases.<sup>7,30</sup> The optimum method of treatment of traumatic knee dislocation has not yet been established. Conservative management usually consists of closed manipulation and immobilization in a hinged brace. Taylor et al.<sup>9</sup> compared 26 knees managed by closed reduction and immobilization with 16 treated

operatively. They reported good results in 18 of those in the group managed conservatively whereas only 4 of 16 knees undergoing surgery had good results. Only 3 of these knees had primary ligamentous repair. Thomsen et al.<sup>34</sup> reported on a series of 10 patients, 4 of whom were treated conservatively and 6 by surgery. Of the latter group, 5 had repair of all ruptured ligaments and 1 of the lateral ligament only. Of these 6 patients, 3 had good outcomes, 2 had fair outcomes, and 1 had a poor outcome. The poor result was in the patient who had repair of the lateral ligament only. The authors concluded that operative treatment was indicated for patients with severe instability and that a satisfactory result could be obtained with either operative or nonoperative treatment.

Other authors advise reconstruction of the ruptured ACL and PCL after dislocation of the knee. Kennedy<sup>11</sup> repaired the collateral and cruciate ligaments in 6 knees and stated that early repair of major ligaments can result in good function. Meyers and Harvey<sup>12</sup> undertook repair of all ruptured ligaments. They reported an excellent outcome in 3 of 16 knees, good in 10, fair in 2, and poor in 1. Sisto and Warren<sup>16</sup> described 20 dislocated knees, 16 of which had been treated surgically and 4 conservatively. Their major reported complication was loss of movement, but they nevertheless recommended surgical treatment in the young active patient. They also advised the use of manipulation under anesthesia if joint flexion was poor. Frassica et al.<sup>10</sup> reported on 17 patients with knee dislocation, 13 of whom were treated by repair or reconstruction of the injured ligaments. Of the 12 who were followed up, 5 had an excellent outcome, 6 had a good outcome, and 1 had a fair outcome. Three patients were treated conservatively, and they had a less favorable result. Shelbourne et al.<sup>35</sup> described ligamentous reconstruction in 3 patients. The ACL and PCL were repaired in 1, and 3 had an isolated PCL autograft. They noted that repair or reconstruction of all the injured ligaments yielded a stable but stiff knee. It was believed that treating the injury to the PCL alone could provide a stable knee with a good range of movement. Their current treatment is reconstruction

**TABLE 4.** *IKDC Rating*

IKDC Result	No. of Knees
Normal knee	—
Nearly normal knee	9
Abnormal knee	9
Severely abnormal knee	2

of the PCL with an autograft and early aggressive rehabilitation. Shapiro and Freedman<sup>17</sup> have reported a consistent approach, although they used allograft rather than autologous graft. They reported satisfactory results in 6 of 7 patients at a mean of 4 years' follow-up.

Ibrahim<sup>20</sup> has reported a consistent approach using autologous graft followed by an aggressive rehabilitation program with excellent or good results. Wascher et al.<sup>18</sup> reviewed the results in 13 patients who underwent simultaneous allograft reconstruction of both the ACL and PCL after a knee dislocation (9 acute and 4 chronic). They reported that reconstruction of both the ACL and PCL for traumatic knee dislocation could improve stability in these severely unstable knees. They recommended early reconstruction to yield results superior to those after late reconstruction, although minor residual PCL laxity was common. The normal range of movement was regained in most patients. Noyes and Barber-Westin<sup>36</sup> reported on 11 patients (7 acute and 4 chronic) who had ACL and PCL reconstruction via an allograft. Patients who had early reconstruction had a higher overall rating than those who had delayed reconstruction. ACL stability was achieved more frequently than PCL stability. Harner et al.<sup>19</sup> reported that surgical treatment of knee dislocation in their series using allograft for reconstruction provided satisfactory subjective and objective outcomes at 2 to 6 years postoperatively. The patients who were treated acutely had higher subjective scores and better objective restoration of knee stability than those treated 3 weeks or more after injury. Nearly all patients were able to perform daily activities with few problems. However, the ability of patients to return to higher-demand sports and strenuous manual labor was less predictable.

Fanelli et al.<sup>37</sup> reported that arthroscopically assisted combined ACL and PCL reconstruction with appropriate collateral ligament surgery is a reproducible procedure. Knee stability improved postoperatively. They also reported that acute medial collateral ligament tears when combined with ACL and PCL tears in certain cases should be treated with bracing whereas posterolateral corner injuries combined with ACL and PCL injuries are best treated with primary repair.

Chuang et al.<sup>38</sup> reported on a 3-stage program for treatment of traumatic knee dislocation that produced adequate stability, range of movement, and knee function; they described a posterior inlay technique for PCL reconstruction and suspension fixation for ACL

reconstruction, representing reasonable alternative methods for definite treatment of knee dislocation.

Our results are comparable to those in other series of patients who had reconstruction of their cruciate ligaments after traumatic knee dislocation with allografts<sup>17,19,28</sup> despite the fact that we used autologous graft. On the basis of these results for reconstruction of acute cases, we advocate reconstruction of both cruciate ligaments and repair of collateral or capsular injuries. Some surgeons have advocated delayed reconstruction.<sup>30</sup> The timing of surgery in our series (2 to 3 weeks) did not increase the rate of arthrofibrosis; this was a result of our use of the CPM machine to achieve a good range of movement before surgery, as well as its use postoperatively with our rehabilitation protocol. We favor the use of autologous graft rather than allograft because allograft requires special preparation and storage and is expensive, and we have no experience in using it despite the fact that the use of allograft avoids surgical morbidity. To assess functional disability, we used the Lysholm knee scale, the Meyers scale, and the activities scales of the Knee Outcome Survey. The Lysholm score for our patients (91 points) was comparable to that in other reports for acute cases.<sup>17,19,28</sup> The Meyers ratings in our series were similar to those in other reports.<sup>15,17,19,28</sup> Ninety percent of our patients received an excellent or good rating, meaning that most of our patients were able to return to their previous activities with minimal instability and pain. The outcome survey showed that most of our patients were satisfied with their results. On the IKDC rating scale, no knee was reported as normal in our series, whereas knees reported as nearly normal or abnormal had high Lysholm, Meyers, and Knee Outcome Survey scores. This is because the IKDC rating assesses subjective, objective, and functional disability, whereas the Meyers scoring system is the only scale especially designed to evaluate treatment of dislocated knees. It is a subjective scale. The Lysholm scale is also mainly subjective. This study shows that reconstruction of injured ligaments yields good functional results. Our aim was to restore the normal kinematics of the knee to prevent or delay the onset of degenerative changes.

## CONCLUSIONS

By use of the described method of arthroscopically assisted reconstruction of the cruciate ligaments and repair or reconstruction of the collateral ligament and other injured structures, 45% of the patients had good subjective results and functional stability, and 45%

had satisfactory subjective and functional stability within 2 to 3 weeks after surgery. According to the IKDC scale, 45% of knees were nearly normal, 45% were abnormal, and 10% were severely abnormal. No patient's knee returned to normal.

## REFERENCES

- Siliski JM. Evaluation and treatment of dislocation of the knee. *Mediguide Orthop* 1992;10:1-7.
- Green NE, Allen BL. Vascular injuries associated with dislocation of the knee. *J Bone Joint Surg Am* 1977;59:236-239.
- Osmond Clark H. Dislocation of the knee joint with capsular interposition. *Proc R Soc Med* 1942;35:759.
- Quinlan AG. Irreducible posterolateral dislocation of the knee with button-holing of the medial femoral condyle. *J Bone Joint Surg Am* 1966;48:1619-1621.
- Quinlan AG, Sharrard WJW. Postero-lateral dislocation of the knee with capsular interposition. *J Bone Joint Surg Br* 1958; 40:660-663.
- Cooper DR, Speer KP, Wickiewicz TL, Warren RF. Complete knee dislocation without posterior cruciate ligament disruption: A report of four cases and review of the literature. *Clin Orthop Relat Res* 1992;228-233.
- Shelbourne KD, Pritchard J, Retting AC, McCarroll JR, Vanmijeter CD. Knee dislocations with intact PCL. *Orthop Rev* 1992;21:607-608, 610-611.
- Reckling FW, Peltier LF. Acute knee dislocations and their complications. *J Trauma* 1969;9:181-191.
- Taylor AR, Arden GP, Rainey HA. Traumatic dislocation of the knee: A report of forty-three cases with special reference to conservative treatment. *J Bone Joint Surg Br* 1972;54:96-102.
- Frassica FJ, Sim FH, Staeheli JW, Pairolo PC. Dislocation of the knee. *Clin Orthop Relat Res* 1991;200-205.
- Kennedy JC. Complete dislocation of the knee joint. *J Bone Joint Surg Am* 1963;45:889-904.
- Meyers MH, Harvey JP Jr. Traumatic dislocation of the knee joint. A study of eighteen cases. *J Bone Joint Surg Am* 1971; 53:16-29.
- Montgomery JB. Dislocation of the knee. *Orthop Clin North Am* 1987;18:149-156.
- Roman PF, Hopson CN, Zennin EJ. Traumatic dislocation of the knee: A report of 30 cases and literature review. *Orthop Rev* 1987;16:917-924.
- Shields L, Mital M, Cave EF. Complete dislocation of the knee: Experience at the Massachusetts General Hospital. *J Trauma* 1969;9:192-215.
- Sisto DJ, Warren RF. Complete knee dislocation: A follow-up study of operative treatment. *Clin Orthop Relat Res* 1985;94-101.
- Shapiro MS, Freedman EL. Allograft reconstruction of the anterior and posterior cruciate ligaments after traumatic knee dislocation. *Am J Sports Med* 1995;23:580-587.
- Wascher DC, Becker JR, Dexter JG, Blevins FT. Reconstruction of the anterior and posterior cruciate ligaments after knee dislocation. Results using fresh-frozen nonirradiated allografts. *Am J Sports Med* 1999;27:189-196.
- Harner CD, Waltrip RL, Bennett CH, Francis KA, Cole B, Irrgang JJ. Surgical management of knee dislocations. *J Bone Joint Surg Am* 2004;86:262-273.
- Ibrahim SA. Primary repair of the cruciate and collateral ligaments after traumatic dislocation of the knee. *J Bone Joint Surg Br* 1999;81:987-990.
- Ibrahim SA. Clinical evaluation of arthroscopically assisted anterior cruciate ligament reconstruction: Patellar tendon versus gracilis and semitendinosus autograft. *Arthroscopy* 2005; 21:412-417.
- Nau T, Lavoie P, Duval N. A new generation of artificial ligaments in reconstruction of the anterior cruciate ligament. Two-year follow-up of a randomised trial. *J Bone Joint Surg Br* 2002;84:356-360.
- Ranger P, Berry G, Talbot M, Fernandez J. Treatment of acute dislocations using synthetic ligaments. *J Bone Joint Surg* 2002;84:141-144.
- Talbot M, Berry G, Fernandes J, Ranger P. Knee dislocations: Experience at the Hôpital du Sacré-Coeur de Montréal. *Can J Surg* 2004;47:20-24.
- Irrgang JJ, Snyder-Mackler L, Wainner RS, Fu FH, Harner CD. Development of a patient-reported measure of function of the knee. *J Bone Joint Surg Am* 1998;80:1132-1145.
- Borsa PA, Lephart SM, Irrgang JJ. Sport-specificity of knee scoring systems to assess disability in anterior cruciate ligament-deficient athletes. *J Sports Rehabil* 1998;7:44-60.
- Meyers MH, Moore TM, Harvey JP Jr. Traumatic dislocation of the knee joint. *J Bone Joint Surg Am* 1975;57:430-433.
- Tegner Y, Lysholm J. Rating systems in the evaluation of knee ligament injuries. *Clin Orthop Relat Res* 1985:43-49.
- Hefti F, Muller W, Jakob RP, Staubli HU. Evaluation of knee ligament injuries with the IKDC form. *Knee Surg Sports Traumatol Arthrosc* 1993;1:226-234.
- Jones RE, Smith EC, Bone GE. Vascular and orthopaedic complications of knee dislocation. *Surg Gynecol Obstet* 1979; 149:554-558.
- Welling RE, Kakkasseril J, Cranley JJ. Complete dislocation of the knee with popliteal vascular injury. *J Trauma* 1981;21: 450-453.
- Kremchek TE, Welling RE, Kremchek EJ. Traumatic dislocation of the knee. *Orthop Rev* 1989;18:1051-1057.
- O'Donnell TF Jr, Brewster DC, Darling RC, Veen H, Waltmann AA. Arterial injuries associated with fractures and/or dislocations of the knee. *J Trauma* 1977;17:775-784.
- Thomsen PB, Rud B, Jensen UH. Stability and motion after traumatic dislocation of the knee. *Acta Orthop Scand* 1984; 55:278-283.
- Shelbourne KD, Wilckens JH, Mollabashy A, DeCarlo M. Arthrofibrosis in acute anterior cruciate ligament reconstruction: The effect of timing of reconstruction and rehabilitation. *Am J Sports Med* 1991;19:332-336.
- Noyes FR, Barber-Westin SD. Reconstruction of the anterior and posterior cruciate ligament after knee dislocation. Use of early protected postoperative motion to decrease arthrofibrosis. *Am J Sports Med* 1997;25:769-778.
- Fanelli GC, Orcutt DR, Edson CJ. The multiple-ligament injured knee: Evaluation, treatment, and results. *Arthroscopy* 2005;21:471-486.
- Chuang T-Y, Ho W-P, Hsieh P-H, Yu S-W, Chen Y-J, Chen C-H. One-stage posterior cruciate ligament inlay reconstruction combining anterior cruciate ligament reconstruction following knee dislocation. *Arthroscopy* 2006;22:339.e1-339.e7. Available online at [www.arthroscopyjournal.org](http://www.arthroscopyjournal.org).